



PATIENT

Holly Missimer

SPECIES

Canine

BREED

Brittany Spaniel

SEX

Female Spayed

AGE

12 years

WEIGHT

27.5lbs

INTERPRETED BY

Maggie Machen
Lamy, DVM
DACVIM (Cardiology)

IMAGING PERFORMED BY

Pamela Harrigan,
RDCS

HOSPITAL NAME

Norfolk County
Veterinary Service

REFERRING VET

Dr. Poor

INVOICE

29811

DATE

3/23/23

PRESENTING CLINICAL SIGNS

History: Recheck echo. History chronic valvular disease- Stage B1. No clinical signs. BP: 111, 112, 112mmHg.

-Pertinent previous echo findings (9/30/22 MML): LA 3.2 cm, LA: Ao 1.45, LV 4.1 cm, mild LAE, mild-moderate MR, mild TR.

ECHOCARDIOGRAM FINDINGS

2D, m-mode, color flow and Doppler imaging is available.

Left ventricle: The LV diameter is increased with adequate myocardial function. LV wall thicknesses are normal.

Left atrium: The left atrium is moderately dilated with a horizontal component.

Mitral valve: The mitral valve is mildly thickened with prolapse into the left atrial lumen. Moderate eccentric mitral regurgitation with a normal velocity.

Aortic valve/aorta: The aortic valve is normal in morphology and mobility. Normal aortic outflow velocity; laminar flow. No aortic insufficiency.

Right ventricle: Normal right ventricular diameter and morphology indicating no overt evidence of pulmonary arterial hypertension.

Right atrium: Normal RA dimension.

Tricuspid valve: The tricuspid valve appears normal with mild tricuspid regurgitation. Normal velocity.

Pulmonic valve/pulmonary artery: The pulmonic valve is normal in morphology and mobility. No pulmonic insufficiency. Normal RVOT velocity; laminar flow.

Pericardium/other: No pericardial or pleural effusion noted. No obvious cardiac masses.

Heart rhythm: ECG reveals a sinus rhythm with an average HR of 100bpm.

2-Dimensional Measurements

Ao diam (cm)	2.3
LA diam (cm)	3.9
LA:Ao (Swe)	1.7
IVS thickness (cm)	0.9
LVID diastole (cm)	4.6
PW thickness (cm)	0.9
LVID systole (cm)	2.5
FS (%)	45

Doppler Measurements

PV Vmax (m/s)	0.6
AoV Vmax (m/s)	1.2
MR Vmax (m/s)	4.7
TR Vmax (m/s)	2.4
TR PG (mmHg)	23

INTERPRETATION OF THE FINDINGS

Chronic degenerative valve disease persists with moderate mitral and mild tricuspid regurgitation. Compared to the prior study, there is certainly evidence of progression with increased left heart dimensions. Moderate left atrial enlargement indicates there is relatively low risk for imminent complication; however, risk for progression to spontaneous congestive heart failure in the future is elevated. No additional issues such as pulmonary hypertension have developed.

Given LA dilation, Pimobendan is recommended as below. Continued assessment of progression in the future will help predict long term outcome; however, prognosis is guarded at this stage (B2).



PATIENT

Holly Missimer

SPECIES

Canine

BREED

Brittany Spaniel

SEX

Female Spayed

AGE

12 years

WEIGHT

27.5lbs

INTERPRETED BY

Maggie Machen Lamy, DVM
DACVIM (Cardiology)

IMAGING PERFORMED BY

Pamela Harrigan, RDCS

HOSPITAL NAME

Norfolk County Veterinary Service

REFERRING VET

Dr. Poor

INVOICE

29811

DATE

3/23/23

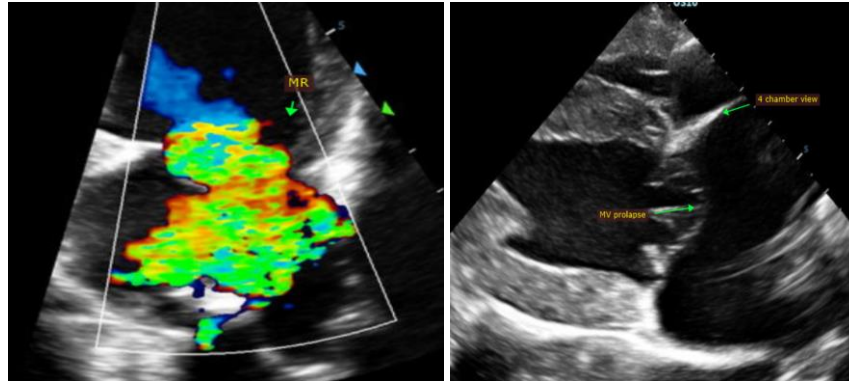
RECOMMENDATIONS

- Institute heart muscle support Pimobendan 0.3mg/kg PO q12h.
- Omega fatty acid supplementation and mild salt restriction may be of some long-term benefit.
- Once on Pimobendan for 3-5 days, anesthetic risk is considered mild if needed. Cardiac protective drug choices (opioid/benzodiazepine premedication, propofol or alfaxalone induction, isoflurane gas) are recommended. Pre-oxygenate for 5-10 minutes prior to induction. Monitor for arrhythmias, hypotension, and hypoxia both intra and post-operatively and intervene as necessary. Mild IV fluid restriction is recommended to avoid fluid overload. Avoid heart rate stimulating drugs such as atropine unless clinically indicated.
- Monitor for development of a cough, labored breathing, exercise intolerance or collapse episodes.

PLAN

- Recommend conservative monitoring with a recheck echocardiogram in 6 months, sooner if any development of clinical signs.

IMAGES



The information and recommendations provided are based on the images presented by the referring veterinarian. No evaluation can be communicated regarding pathology that was not visible in the image/video clips provided.

Thank you for this referral. This report was generated using transcription software, and minor dictation errors may be present. If the clinical or image interpretation does not parallel your findings or if I can be of any further assistance, please contact me.

Maggie Machen Lamy, DVM
Diplomate of the American College of Veterinary Internal Medicine (Cardiology)
info@sonopath.com

Echocardiogram performed by: Pamela Harrigan, RDCS
Pet Animal Ultrasound Service (4paus.com)